

Protective Effect of Citric Acid Against Thioacetamide-Induced Oxidative Stress and Liver Tissue Damage

Omar M.E.Abdel-Salam^{a,1,*}, Eman R. Youness^b, Amany A. Sleem^c, Fatma A. Morsy^d

^a Department of Toxicology and Narcotics, Medical Research and Clinical Studies Institute, National Research Centre, Cairo, Egypt

^b Department of Medical Biochemistry, Medical Research and Clinical Studies Institute, National Research Centre, Cairo, Egypt

^c Department of Pharmacology, Medical Research and Clinical Studies Institute, National Research Centre, Cairo, Egypt

^d Department of Pathology, Medical Research and Clinical Studies Institute, National Research Centre, Cairo, Egypt

¹ omar_abdelsalam@yahoo.com

* corresponding author

ARTICLE INFO

Article history

Received January 17, 2023

Revised April 11, 2023

Accepted June 7, 2023

Keywords:

citric acid

thioacetamide

liver

oxidative stress

ABSTRACT

The effect of citric acid on liver and brain oxidative stress and liver tissue damage was studied. Rats were treated with thioacetamide at 300 mg/kg, intraperitoneally, for two successive days alone or together with orally administered citric acid at doses of 0.4 g/kg or 1g/kg. Rats were euthanized 24h after last treatments and their livers and brains were dissected out for determination of malondialdehyde (MDA), reduced glutathione (GSH), nitric oxide, and paraoxonase-1 (PON-1). Serum alanine aminotransferase and aspartate aminotransferase were determined and histological investigation for the liver tissue was carried out. Results showed that compared with the saline control, treatment with thioacetamide caused marked increase in liver and brain MDA and NO together with GSH depletion and inhibition of PON-1 activity. Serum aminotransferases were markedly increased in thioacetamide-treated rats. The histologic study showed distorted liver architecture, necrotic and apoptotic hepatocytes, fatty change, and ballooning degeneration. Citric acid reduced the increases in liver and brain MDA and NO contents and markedly increased GSH level and PON-1 activity. It also reduced the increments in activities of serum transaminases. These effects of citric acid were dose-dependent. Histologic examination confirmed that rats treated with citric acid at 1g/kg had markedly reduced liver damage. In conclusion, 1g/kg citric acid given at time of thioacetamide administration markedly reduced oxidative stress in both the liver and brain tissue and was able to restore liver architecture.

This is an open access article under the [CC-BY-SA](https://creativecommons.org/licenses/by-sa/4.0/) license.



1. Introduction

Oxidative stress is considered an important pathogenetic mechanism that underlies hepatocyte cell death in several liver pathologies. In addition, oxidative stress drives liver fibrogenesis by increasing the production of a number of cytokines including transforming grown factor- β (TGF- β), tumor necrosis factor- α (TNF- α) and interleukin-6 (IL-6). Reactive oxygen species (ROS) are produced during normal cellular metabolism and participate in cell physiological processes eg., cell

signaling and apoptosis (Videla, 2009; Vascotto and Tiribelli, 2015). Reactive oxygen species derives from multiple sources, the most important being the mitochondria where the leakage of electrons onto molecular oxygen results in the formation of superoxide ($O_2^{\cdot-}$). The reaction between nitric oxide and superoxide produces peroxynitrite ($ONOO^-$). In addition, superoxide can be dismutated to hydrogen peroxide (H_2O_2) and oxygen by the enzyme superoxide dismutase. Moreover, the reaction of hydrogen peroxide with the reduced forms of the transition metal ions e.g., Fe^{2+} , Cu^+ can result in the generation of the oxidant hydroxyl radical (HO^{\cdot}) (Gutteridge and Halliwell, 1999). In inflammation, ROS can be produced in excess from activated phagocytes, Kupffer cells, activated hepatic stellate cells and infiltrating neutrophils that release $O_2^{\cdot-}$, H_2O_2 , and hypochlorous acid (HOCl) and from activated lipoxygenase and cyclooxygenase (Halliwell, 2001). The cell is protected from ROS by a number of antioxidants including enzymes such as superoxide dismutases, catalases, and peroxidases, and low-molecular-mass scavengers e.g., vitamin E, ascorbate, urate, glutathione, and ubiquinol. There are also a number of exogenous or dietary antioxidants that include vitamin E, ascorbate, flavonoids, and carotenoids (Sies, 1997; Gutteridge and Halliwell, 1999). When antioxidants are deficient or overwhelmed by an excess of free radicals, the redox-balance in the cell shifts towards the oxidant side and the state of oxidative stress is said to be present (Halliwell, 2006). The result is oxidative damage with cell membrane lipid peroxidation, DNA oxidation, enzyme inactivation and resulting cellular metabolic derangement or cellular death (Valko et al., 2007).

Citric acid is a weak organic acid, a natural constituent and common metabolite in plant and animal tissues. Citric acid is found in the greatest levels in the juices of citrus fruits such as lemon, orange, grapefruit and tangerine juices. It is also present in considerable amounts in non-citrus fruits, such as strawberries, pineapples, and raspberries (Hoyt and Gewanter, 1992). Dietary citrate is rapidly and nearly totally absorbed in the small intestine causing rapid increase in serum citrate concentration (Fegan et al., 1992; Abdel-Salam et al., 2018). Citrate metabolism primarily occurs in the liver and kidneys (Bashir et al., 2012). At physiological pH values, citric acid is present mainly in its dissociated trivalent form, citrate³⁻ (Hess, 2011). Citrate mainly circulates unbound to larger molecules with human plasma concentrations between 0.05 and 0.3 mmol/l (Unwin et al., 2004). Intracellular citrate is a central component of the tricarboxylic acid cycle (Krebs' cycle). Citrate, the first Krebs cycle intermediate, is produced in the mitochondria from acetyl-CoA and oxalacetate and enters the citric acid or tricarboxylic acid cycle which is the final common pathway for the oxidation of carbohydrates, fatty acids and amino acids and is the main source of energy in the cell in the form of adenosine 5'-triphosphate (ATP) (Fromm and Hargrove, 2012).

The administration of high doses of thioacetamide is a reliable and widely used model of acute liver failure and encephalopathy and to investigate potential therapeutic approaches. The toxic action of thioacetamide (TAA) on hepatocytes and cholangiocytes is mediated by its metabolites TAA-S-oxide and TAA-S,S-oxide generated by hepatic cytochrome P450 enzymes or FAD-containing monooxygenases. These reactive metabolites of thioacetamide causes oxidative stress, glutathione depletion and covalently bind to cellular proteins and lipids resulting in centrilobular necrosis and inflammation (Wallace et al., 2015).

The aim of this study was therefore to: (1) evaluate the effect of administering citric acid on oxidative stress in the brain and liver in rats intoxicated with thioacetamide; (2) investigate the protective potential of citric acid against liver tissue damage induced by thioacetamide.

2. Materials and methods

2.1. Animals

Male Sprague-Dawley strain rats (150-160 g; National Research Centre, Cairo) were used in the experiments. Rats were housed under a standard 12-h light/dark cycle and had free access to food and water. Animal procedures followed the guidelines of the Institute ethics committee for the use of animals in experimental studies and the Guide for Care and Use of Laboratory Animals by the U.S. National Institutes of Health (Publication No. 85-23, revised 1996).

2.2. Drugs and chemicals

Thioacetamide and citric acid were obtained from Sigma-Aldrich (St Louis, MO, USA). Other chemicals and reagents were obtained from Sigma Chemical Co. (St. Louis, MO, U.S.A.).

2.3. Experimental groups

Rats were randomly allocated into four equal groups (6 rats each). Group 1 received saline and served as -ve control. Groups 2, 3 & 4 were treated with thioacetamide at 300 mg/kg, intraperitoneally, for two successive days alone (group 2) or together with orally administered citric acid at doses of 0.4 g/kg or 1g/kg (groups 3 & 4). Rats had free access to food and drinking water during the study. 24h after last treatments, blood samples were obtained from the retro-orbital vein plexuses, under light ether anaesthesia. Rats were then euthanized by cervical decapitation under ether anaesthesia. The brain and liver of each rat were then quickly removed, washed with ice-cold phosphate-buffered saline (PBS, pH 7.4), weighed, and stored at -80°C until the biochemical analyses were carried out. The tissues were homogenized in 0.1 M phosphate-buffered saline at pH 7.4 to give a final concentration of 10 % w/v for the biochemical assays. The histopathological study was carried out on separate groups of rats (n = 4 per group).

2.4. Biochemical assays

2.4.1. Lipid peroxidation assay

Lipid peroxidation was measured by determining the level of malondialdehyde (MDA), a lipid breakdown end product according to the method described by Nair and Turne (1984). In this method, thiobarbituric acid reactive substances (TBAS) react with thiobarbituric acid forming TBA-MDA adduct and the absorbance is read at 532 nm using spectrophotometer.

2.4.2. Nitric oxide assay

The level of nitric oxide, measured as nitrite, was determined using the Griess reagent. Nitrite, a stable end-product of nitric oxide, is used as an indicator of the production of nitric oxide. In this assay, nitrate is converted to nitrite by nitrate reductase. The Griess reagent then reacts with nitrite forming a deep purple azo compound. The absorbance is read at 540 nm using a spectrophotometer (Archer, 1993).

2.4.3. Reduced glutathione assay

Reduced glutathione (GSH) was determined in homogenates according to Ellman (1959). Briefly, DTNB (5,5'-dithiobis (2-nitrobenzoic acid) or Ellman's reagent is reduced by the free sulfhydryl group on GSH molecule to generate the yellow colored 5-thio-2-nitrobenzoic acid which can be determined by reading absorbance at 412 nm.

2.4.4. Paraoxonase-1 assay

The arylesterase activity of PON-1 was determined by a colorimetric method using phenyl acetate as a substrate. In this assay, PON-1 catalyzes the cleavage of phenyl acetate resulting in phenol formation. The rate of formation of phenol was measured by monitoring the increase in absorbance at 270 nm at 25°C . The working mix consisted of 20 mM Tris/HCl buffer, pH 8.0, containing 1 mM CaCl_2 and 4 mM phenyl acetate as the substrate. Samples diluted 1:3 in buffer were added to the above mix and the changes in absorbance were recorded following a 20s lag time. One unit of arylesterase activity is equal to 1 μmole of phenol formed per min. The PON-1 activity is expressed in kU/l, based on the extinction coefficient of phenol of $1310 \text{ M}^{-1}\text{cm}^{-1}$. Blank samples containing water were used to correct for the spontaneous hydrolysis of phenyl acetate (Haagen and Brock, 1992).

2.5. Serum liver enzymes assay

The activities of the liver enzymes alanine aminotransferase (ALT) and aspartate aminotransferase (AST) in serum were measured according to Reitman–Frankel colorimetric transaminase procedure (Crowley, 1967).

2.6. Liver histopathology

Liver tissues were fixed in 10% buffered formalin, dehydrated in graded ethanol, and embedded in paraffin using standard procedures. Sections of 5 μm thickness were stained with hematoxylin and eosin (H&E) for histopathological examination using a light microscope.

2.7. Statistical analysis

Results are expressed as mean \pm SE. Data were statistically analyzed using one way analysis of variance (ANOVA) followed by Tukey's multiple comparisons test for multiple group comparison. GraphPad Prism 6 for Windows (GraphPad Prism Software Inc., San Diego, CA, USA) was used. Statistical significance was considered at a probability value of less than 0.05.

3. Results

3.1. Liver parameters

3.1.1. Lipid peroxidation

Significant increase in MDA content by 69.7% was observed in liver of thioacetamide-treated animals compared with their saline control (57.6 ± 3.1 vs. 32.4 ± 2.0 nmol/g.tissue). Treatment with citric acid 1 g/kg resulted in significant decrease in liver MDA by 31.4% (39.9 ± 2.4 vs. 57.6 ± 3.1 nmol/g.tissue) (Fig. 1).

3.1.2. Nitric oxide

Rats treated with thioacetamide exhibited significant increase in liver nitric oxide content by 73.8% compared with the saline control (65.7 ± 1.5 vs. 37.8 ± 0.6 $\mu\text{mol/g.tissue}$). Citric acid given at 1g/kg significantly decreased nitric oxide level by 38.8% as compared to the thioacetamide control (40.2 ± 1.1 vs. 65.7 ± 1.5 $\mu\text{mol/g.tissue}$) (Fig. 1).

3.1.3. Reduced glutathione

Following thioacetamide injections, there was a significant decrease in liver GSH level by 48.3% compared with the saline control (4.0 ± 0.15 vs. 7.74 ± 0.18 $\mu\text{mol/g.tissue}$). Citric acid given at 1g/kg significantly increased GSH level by 60.8% as compared to the thioacetamide control (6.43 ± 0.3 vs. 4.0 ± 0.15 $\mu\text{mol/g.tissue}$) (Fig. 1).

3.1.4. Paraoxonase-1

PON-1 activity in the liver was significantly decreased by 50.8% after thioacetamide injections compared with the saline group (15.5 ± 0.4 vs. 31.5 ± 1.0 kU/l). Citric acid given at 0.4 g/kg and 1 g/kg resulted in significant increase 37.4% and 76.8% in PON-1 activity compared with thioacetamide control value (21.3 ± 0.6 and 27.4 ± 0.8 vs. 15.5 ± 0.4 kU/l) (Fig. 1).

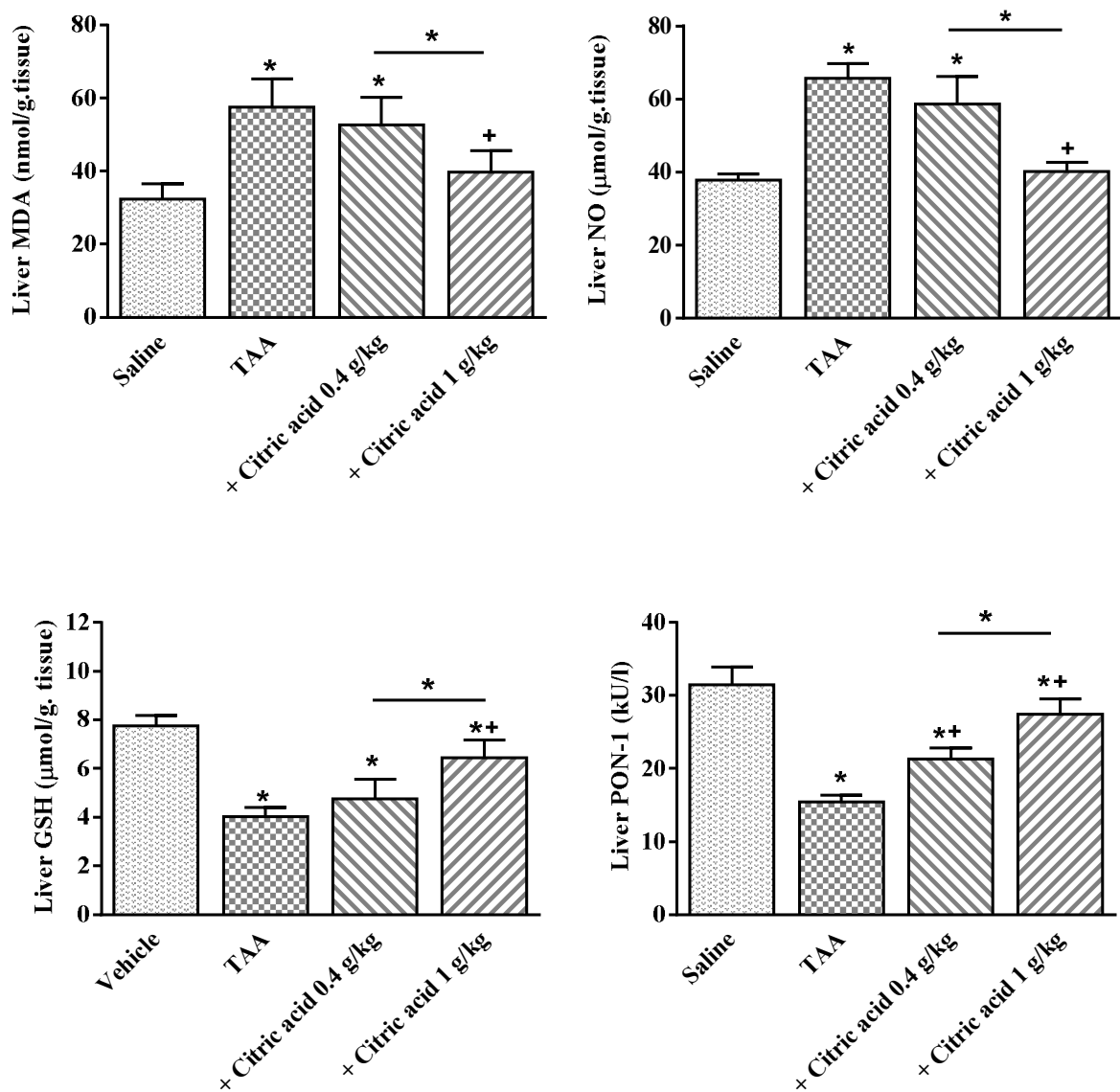


Fig. 1. Effect of citric acid on liver malondialdehyde (MDA), nitric oxide (NO), reduced glutathione (GSH), paraoxonase-1 (PON-1) activity in thioacetamide (TAA)-treated rats. *: $P < 0.05$ vs. saline control. +: $P < 0.05$ vs. TAA only group and between different groups as shown in the graph.

3.2. Brain parameters

3.2.1. Lipid peroxidation

Thioacetamide administration caused significantly increased brain MDA level by 67.1% compared with the saline control group (32.9 ± 1.3 vs. 19.7 ± 0.7 nmol/g.tissue). Treatment with citric acid 0.4g/kg had no significant effect on MDA level. The higher dose of 1g/kg, however, reduced MDA by 29.7% (23.1 ± 0.8 vs. 32.9 ± 1.3 nmol/g.tissue) (Fig. 2).

3.2.2. Nitric oxide

After thioacetamide administration, the level of brain nitric oxide increased by 53.4% compared with the saline control (36.2 ± 1.9 vs. 23.6 ± 1.2 $\mu\text{mol/g.tissue}$). Significant decrease in brain nitric oxide level by 27.5% was observed after treatment with citric acid 1g/kg (26.3 ± 0.7 vs. 36.2 ± 1.9 $\mu\text{mol/g.tissue}$) (Fig. 2).

3.2.3. Reduced glutathione

A significant decrease in GSH by 65.1% (1.72 ± 0.10 vs. 3.31 ± 0.12 $\mu\text{mol/g.tissue}$) was observed in the brain of thioacetamide-treated rats. Treatment with 0.4 g/kg citric acid increased brain GSH by 15.7% which was not statistically different from thioacetamide control value. Significant increase in brain GSH level by 62.8% was observed after treatment with citric acid 1g/kg (2.8 ± 0.1 vs. 1.72 ± 0.10 $\mu\text{mol/g.tissue}$) (Fig. 2).

3.2.4. Paraoxonase-1

There was a significant decrease in brain PON-1 activity by 67.6% after thioacetamide administration compared with the saline control value (3.3 ± 0.3 vs. 10.1 ± 0.5 kU/l). PON-1 activity increased by 133.8% and 197.6% after citric acid at 0.4 g/kg and 1g/kg, respectively (7.7 ± 0.4 and 9.8 ± 0.5 vs. 3.3 ± 0.3 kU/l) (Fig. 2).

3.3. Serum liver enzymes

After thioacetamide administration, the activities of ALT and AST in serum were significantly raised by 127.3% (155.8 ± 4.96 vs. 68.53 ± 2.75 U/l) and 147.1% (207.9 ± 6.76 vs. 84.13 ± 3.45 U/l), respectively, compared to the corresponding saline control values. The treatment of rats with citric acid at 0.4 g/kg or 1 g/kg significantly decreased serum ALT by 16.0% and 41.5%, respectively compared with thioacetamide control (130.8 ± 4.83 and 80.30 ± 2.1 vs. 155.8 ± 4.96 U/l). Meanwhile, serum AST decreased by 19.4% and 45.6%, respectively by citric acid at 0.4 g/kg or 1 g/kg (from control value of 207.9 ± 6.76 U/l to 167.6 ± 5.72 U/l and 113.1 ± 4.0 U/l) (Fig. 3).

3.3. Liver histopathology

H&E stained sections of liver of the saline control group revealed normal histological appearances of liver tissues, the hepatic lobules arranged in cords radiating from the central veins made of hepatocytes. Normal sinusoidal space is lined by Kupffer cells (Fig.4A) On the other hand, liver tissues from rats treated with thioacetamide only showed disorganized hepatic architecture with marked affection of the hepatocytes in the form of extensive vacuolation of their cytoplasm, fatty change, ballooning degeneration. There were also necrotic hepatocyte are small rounded cells indicative of late stage of apoptosis, dilated portal vein, massive inflammatory cells around the portal tract, dilated congested central vein with thickening of wall, fibrosis, inflammatory cells around the vein and most of the blood sinusoids appeared narrow or obliterated (Fig. 4B-D). Rats treated with thioacetamide and citric acid at 0.4 g/kg showed deformed hepatic architecture. The hepatocytes still suffered from pathological changes in the form of massive vacuolation of their cytoplasm, fatty change, cloudy swelling in some cells, and apoptosis. Red blood cells in dilated blood sinusoids, dilated congested portal vein, hyperplasia of bile duct, pre portal necrosis, fibrosis and thickening of portal vein vascular wall, and inflammatory infiltrate were seen (Fig. 4E-G). The group treated with thioacetamide and high dose of citric acids showed regeneration in the most of hepatocytes. The hepatocytes were polygonal in shape with well preserved cytoplasm, nucleus and prominent nuclei. The sinusoidal space was lined by Kupffer cells but mild cytoplasmic vacuolation and few inflammatory infiltrate were present (Fig. 4H & I).

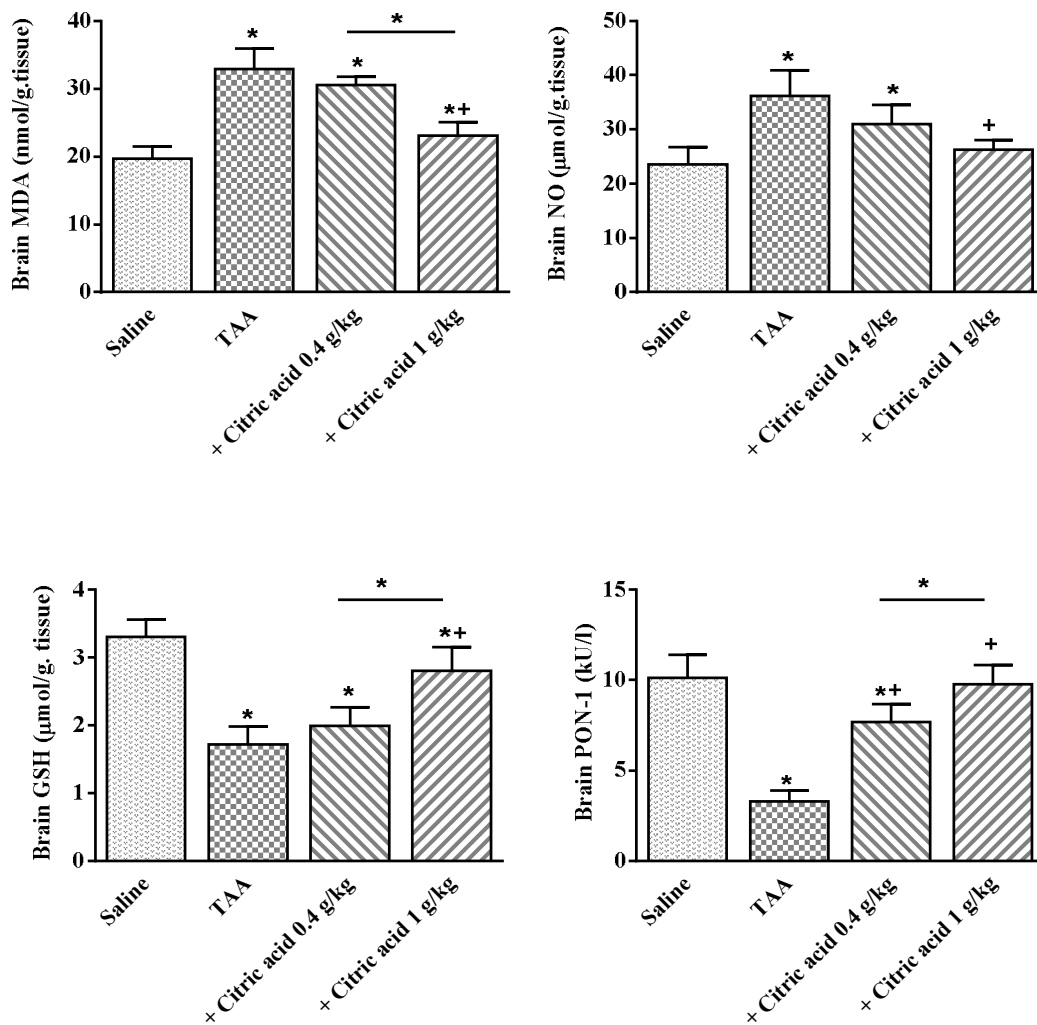


Fig. 2. Brain malondialdehyde (MDA), nitric oxide (NO), reduced glutathione (GSH), paraoxonase-1 (PON-1) activity after treatment with thioacetamide (TAA) alone or in combination with citric acid. *: $P < 0.05$ vs. saline control. +: $P < 0.05$ vs. TAA only group and between different groups as shown in the graph.

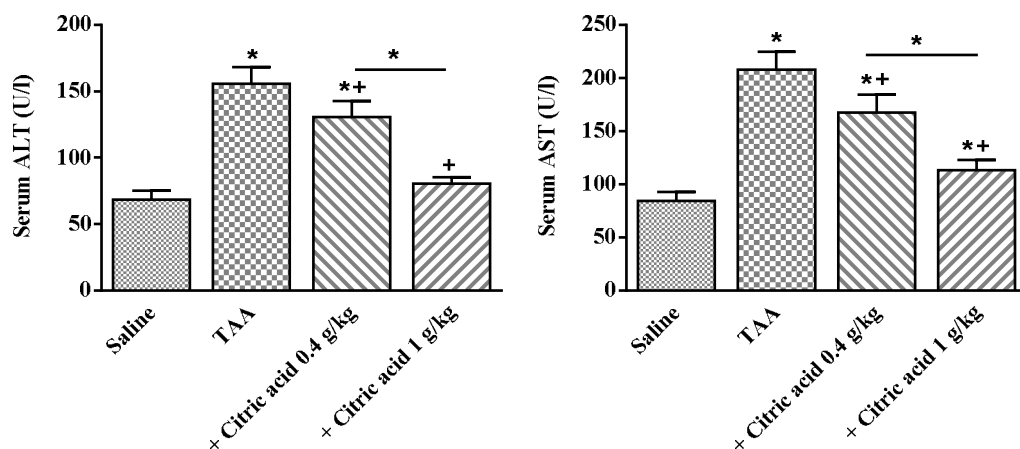


Fig. 3. Serum alanine aminotransferase (ALT) and aspartate aminotransferase in rats treated with thioacetamide (TAA) alone or combined with citric acid. *: $P < 0.05$ vs. saline control. +: $P < 0.05$ vs. TAA only group and between different groups as shown in the graph.

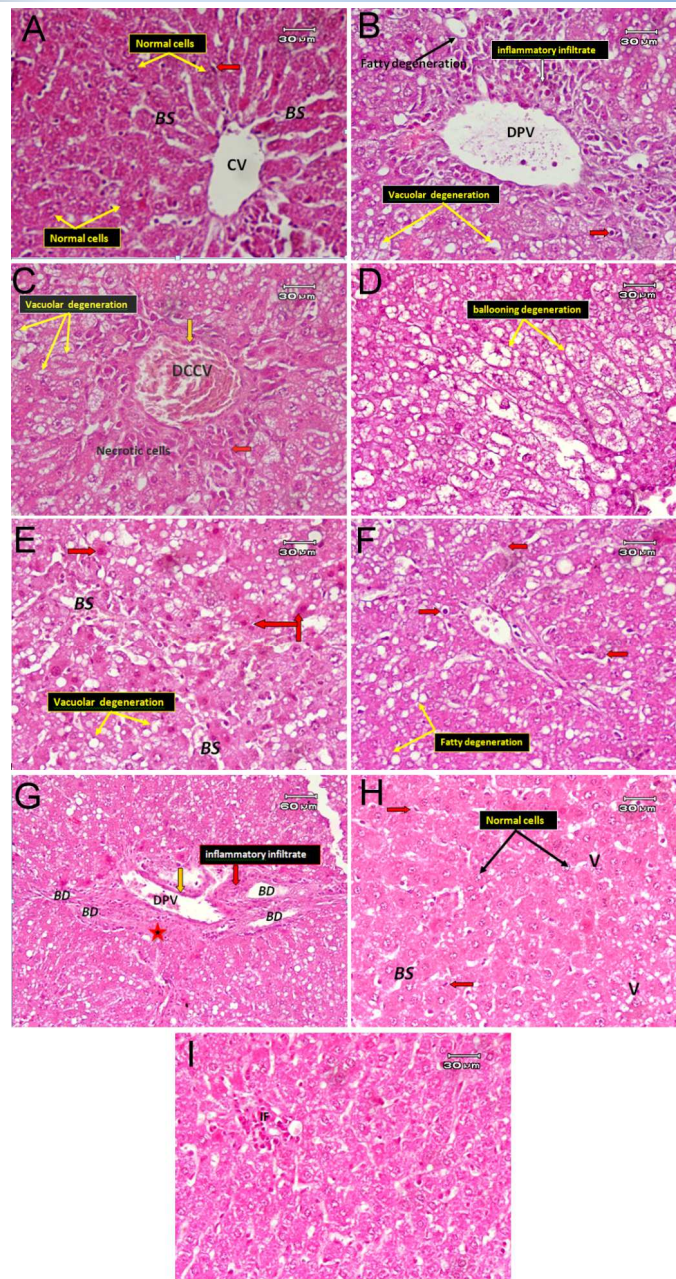


Fig. 4. Representative photomicrographs of Hx & E stained liver sections after treatment with (A) Saline control group showing the classical hepatic architecture. Hepatocytes are arranged in cords radiating from the central vein (CV) and separated by blood sinusoids. The blood sinusoids (BS) separating the hepatic cords are lined by and Kupffer cells (red arrow). (B) Thioacetamide only showing massive vacuolar degeneration (yellow arrow), fatty degeneration (black arrow), dilated portal vein (DPV), inflammatory cells (white arrow), some apoptotic hepatocytes (red arrow). (C) Thioacetamide only (another filed) showed, dilated congested central vein (DCCV) with thickening wall, fibrosis (orange arrow), inflammatory cells (red arrow), and some hepatocyte appeared necrotic. (D) Thioacetamide only (another filed) showing ballooning degeneration (yellow arrow). (E) Thioacetamide and citric at 0.4 g/kg showed massive vacuolar degeneration (yellow arrow), red blood cells in dilated sinusoidal space (BS), cloudy swelling (red arrow). (F) Thioacetamide and citric acid at low dose (another filed) showed some apoptotic cells (red arrow) and fatty degeneration. (G) Thioacetamide and citric acid at 0.4 g/kg (another filed) showing dilated portal vein (DPV), hyperplasia of bile duct (BD), pre-portal necrosis (star), fibrosis and thickening of portal vein vascular wall (orange arrow), and inflammatory infiltrate (red arrow). (H) Thioacetamide and citric acid at 1 g/kg showing histological regeneration in most of hepatocytes being polygonal in shape with nucleus and prominent nuclei (black arrow), normal Kupffer (red arrow) in sinusoidal space although mild cytoplasmic vacuolation were seen. (I) Thioacetamide and citric acid at 1 g/kg (another filed) showing few inflammatory infiltrates (IF).

4. Discussion

The present study used thioacetamide as a model of acute liver injury to investigate the potential therapeutic effect of administering citric acid. Our results indicated that treatment with citric acid caused marked and significant decrease in lipid peroxidation and nitric oxide levels and prevented the depletion in reduced glutathione and the inhibition in paraoxonase-1 activity in both the liver and brain of thioacetamide-intoxicated rats. Citric acid treatment exerted hepatic protective effects evidenced by significant decrease in the plasma levels of the hepatocellular enzymes, improved liver architecture, and decreased hepatocyte necrosis and apoptosis.

The histological observations supported the results obtained from oxidative stress indicators and serum enzyme assays. The sections of livers from thioacetamide-treated rats showed distortion of liver architecture, fatty change, ballooning degeneration, vacuolation, necrotic and apoptotic hepatocytes with massive inflammatory cell infiltrations. These findings are supported by a previous study in which thioacetamide given at single i.p. dose of 300 mg/kg caused loss of hepatic architecture, hydropic degeneration of the hepatocytes, and inflammatory cell infiltration in the portal area (Abdel-Salam et al., 2013). Other researchers reported residual necrosis and infiltration of lymphocytes and macrophages in perivenular area in rats given two i.p. injections of thioacetamide at 350 mg/kg with an interval of 8 h (de David et al., 2011). Moreover, periportal necrosis and severe leucocytic infiltration in the liver followed single intravenous injection of thioacetamide at 280 mg/kg in the rat (Chen et al., 2008). In the present study, sections of livers after treatment with citric acid at 0.4 g/kg did not show histological improvement. Citric acid administered at 1 g/kg, however, led to improved histoarchitecture and regeneration in the most of hepatocytes.

Our results show that citric acid at the doses used in the study had antioxidant effects and reduced oxidative stress in both the liver and brain of thioacetamide-treated rat as evidenced by the decrease in malondialdehyde, the end product of lipid peroxidation end and increased levels of reduced glutathione. Several studies indicated the protective effects of citric acid in models of oxidative stress. In rats, citric acid at 0.4 or 1 g/kg attenuated oxidative stress in the brain and liver, the increase in serum liver enzymes, liver hydropic degeneration and distorted architecture during hypoglycaemia (Abdel-Salam et al., 2022). Citric acid at 1 or 2 g/kg was shown to decrease hepatic DNA fragmentation, and serum transaminases and to prevent liver injury during endotoxaemia. It also increased glutathione peroxidase activity, decreased nitric oxide in brain and liver, and decreased hepatic caspase-3, and iNOS expression (Abdel-Salam et al., 2014). Citric acid exerted beneficial effects upon brain oxidative stress, neuronal injury, histological liver injury and DNA damage of peripheral blood lymphocytes in rats after acute malathion exposure (Abdel-Salam et al., 2016). It also prevented oxidative stress, increased total antioxidant capacity and alleviated the histopathological changes in brain and liver in experimentally-induced Parkinson's disease (Abdel-Salam et al., 2020a). Moreover, citric acid at 1 or 2 g/kg was found to exert antioxidant actions and decrease brain and liver damage evoked by toluene (Abdel-Salam et al., 2020b).

Paraoxonase-1 is an esterase and lactonase involved in the hydrolysis of some organophosphorus insecticides, nerve agent, lipid hydroperoxides and other xenobiotics (La Du BN, 1992). It is synthesized by the liver cells and circulates in blood in association with high density lipoproteins (Watson, 1995). PON1 activities decrease in chronic hepatitis (Ferre et al. 2002), non-alcoholic steatohepatitis (Başkol et al. 2005) and experimental liver injury (Abdel-Salam et al., 2021), and thus could be considered a useful marker of liver injury (Camps et al. 2009). Moreover, the decrease in PON-1 activity in neurological disorders suggests a neuronal protective function for the enzyme that may involve antioxidant and anti-inflammatory actions (Furlong et al., 2016). Here, we show that PON-1 activity is significantly and markedly inhibited in the liver and brain of thioacetamide-treated rats. In a previous study, we also indicated decreased plasma PON-1 activity following repeated thioacetamide injections (Abdel-Salam et al., 2014c).

This decrease in PON-1 activity may be due to decreased synthetic capacity of the liver and/or the inactivation of the enzyme by the presence of an inappropriately high oxidative stress levels and could lead to further decrease in cellular antioxidant capability and increased cell damage. On the other hand, the increase in PON-1 enzyme activity by citric acid clearly supports the biochemical finding of lowered oxidative stress levels and the histological evidence of hepatic regeneration.

Citric acid possesses several pharmacological actions which are relevant to its observed protective effects in the current study. The agent is an antioxidant and is added to human food as a natural preservative to prevent lipid peroxidation due to the presence of carboxyl groups, capable of binding prooxidant Fe^{++} ions (de Carvalho et al., 2010; Kristinova et al., 2014). Supplementation with potassium citrate was reported to decrease oxidative stress in plasma of patients with kidney stones (Tungsanga et al., 2005). The antioxidant action of citric acid has also been shown in animal models of oxidative stress as indicated above. Studies showed inhibition of inducible nitric oxide synthase (iNOS) and consequently the decrease in tissue nitric oxide which is likely to mediate at least in part the protective effects of citric acid (Abdel-Salam et al., 2014a). Low micromolar concentrations of nitric oxide generated by the endothelial and neuronal nitric oxide synthases are important in cell signaling and control of vascular tone. In contrast, the release of higher concentrations of nitric oxide for longer time by iNOS has been shown to cause cell injury via a number of mechanisms that includes peroxynitrite-mediated mitochondrial dysfunction and energy failure (Moncada and Bolanos, 2006; Forstermann and Sessa, 2012). In addition, citric acid down-regulates inflammation by reducing the release of ROS (Gritters et al., 2006), Nuclear factor kappa B (NF- κ B) (Abdel-Salam et al., 2020a), interleukin 1 β (Gabutti et al., 2004), tumour necrosis factor- α (Abdel-Salam et al., 2014a). Citric acid is central to Krebs's cycle, the main source for chemical energy in the cell (Fromm and Hargrove, 2012). Citric acid may thus exert its protective effects by increasing energy production and/or correcting a bioenergetic deficit. There is also evidence for a protective effect for Krebs's cycle substrates such as α -ketoglutarate, pyruvate (Ying et al., 2002; Izumi et al., 2010), oxaloacetate, malate, succinate, citrate (Puntel et al., 2005) or β -hydroxybutyrate (Haces et al., 2008) against neuronal death via antioxidant action.

5. Conclusion

In conclusion, our results show that citric acid has antioxidant effects and prevented liver damage in rats treated with thioacetamide. The effects of citric acid may be beneficial in patients with liver disease.

Acknowledgement

This work was not supported by research grants.

Conflict of interest

The authors declare no conflicts of interest.

References

- [1] Videla, L.A. (2009). Oxidative stress signaling underlying liver disease and hepatoprotective mechanisms. *World Journal of Hepatology*, 1(1), 72-78.
- [2] Vascotto, C., & Tiribelli, C. (2015). Oxidative stress, antioxidant defenses, and the liver. In: *Studies on Hepatic Disorders, Oxidative Stress in Applied Basic Research and Clinical Practice*, (Albano E, Parola M, eds.), Springer International Publishing, Switzerland, pp. 41-64.
- [3] Gutteridge, J.M.C., & Halliwell, B. (1999). Antioxidant Protection and Oxygen Radical Signaling. In: *Reactive Oxygen Species in Biological Systems* (Gilbert and Colton, eds.), Kluwer Academic / Plenum Publishers, New York, pp. 189-218.

- [4] Halliwell, B. (2001). Role of free radicals in the neurodegenerative diseases: therapeutic implications for antioxidant treatment. *Drugs & Aging*, 18(9), 685–716.
- [5] Sies, H. (1997). Oxidative stress: oxidants and antioxidants. *Experimental Physiology*, 82(2), 291–295.
- [6] Halliwell, B. (2006). Oxidative stress and neurodegeneration: where are we now? *Journal of Neurochemistry*, 97, 1634–1658.
- [7] Valko, M., Leibfritz, D., Moncola, J., Cronin, M.T.D., Mazura, M., & Telser, J. (2007). Free radicals and antioxidants in normal physiological functions and human disease. *The International Journal of Biochemistry & Cell Biology*, 39, 44–84.
- [8] Hoyt, H.L., & Gewanter, H.L. (1992). Citrate. In: *The Handbook of Environmental Chemistry*, Vol. 3 Part F, (Hulzinger, O., ed.), Springer-Verlag-Berlin Heidelberg, pp.229- 241.
- [9] Fegan, J., Khan, R., Poindexter, J., & Pak, C.Y. (1992). Gastrointestinal citrate absorption in nephrolithiasis. *Journal of Urology*, 147, 1212-1214.
- [10] Abdel-Salam, O.M.E., Shaffie, N.M., Omara, E.A., & Yassen, N.N. (2018). Citric Acid an Antioxidant in Liver. *The Liver: Oxidative Stress and Dietary Antioxidants* (Patel, V., ed.), Chennai, India, Academic Press, pp. 183-198.
- [11] Bashir, S., Khan, N.A., & Gilani, A-H. (2012). Physiology of renal handling of citrate. In “Urolithiasis” (Talati, J.J. Tiselius H-G, Albala D.M., & Ye Z., eds.), Springer-Verlag, London, pp.183-185. .
- [12] Hess, B. (2011). Urinary citrate and citrate metabolism. In: *Urinary Tract Stone Disease* (Rao et al. eds.), Springer-Verlag London Limited, pp.181-184.
- [13] Unwin, R.J., Capasso, G., & Shirley, D.G. (2004). An overview of divalent cation and citrate handling by the kidney. *Nephron*, 98,15-20.
- [14] Fromm, H.J. & Hargrove, M.S. (2012). The tricarboxylic acid cycle. In: *Essentials of Biochemistry* (Fromm, H.J. & Hargrove, M.S., eds). Springer-Verlag, Berlin, Heidelberg, pp. 205–21.
- [15] Wallace, M.C., Hamesch, K., Lunova, M., Kim, Y., Weiskirchen, R., Strnad, P., & Friedman, S.L. (2015). Standard operating procedures in experimental liver research: thioacetamide model in mice and rats. *Laboratory Animals*, 49(S1), 21–29.
- [16] Nair, V., & Turner, G.A. (1984). The thiobarbituric acid test for lipid peroxidation: structure of the adduct with malondialdehyde. *Lipids*, 19,804–805.
- [17] Archer, S. (1993). Measurement of nitric oxide in biological models. *The FASEB Journal*, 7(2), 349–60.
- [18] Ellman, G.L. (1959). Tissue sulfhydryl groups. *Archives of Biochemistry and Biophysics*, 82, 70–77.
- [19] Haagen, L., & Brock, A. (1992). A new automated method for phenotyping arylesterase (EC 3.1.1.2) based upon inhibition of enzymatic hydrolysis of 4-nitrophenyl acetate by phenyl acetate. *European Journal of Clinical Chemistry and Clinical Biochemistry*, 30,391–395..
- [20] Crowley, L.V. (1967). The Reitman-Frankel colorimetric transaminase procedure in suspected myocardial infarction. *Clinical Chemistry*, 13, 482-487.
- [21] Abdel-Salam, O.M.E., Mohammed, N.A., Sleem, A.A., Farrag, A.R. (2013). The effect of antidepressant drugs on thioacetamide-induced oxidative stress. *European Review for Medical and Pharmacological Sciences*, 17, 735-744.
- [22] de David, C., Rodrigues, G., Bona, S., Meurer, L., González-Gallego, J., Tuñón, M.J., & Marroni, N.P. (2011). Role of quercetin in preventing thioacetamide-induced liver injury in rats. *Toxicologic Pathology*, 39(6), 949-57.
- [23] Chen, T.M., Subeq, Y.M., Lee, R.P., Chiou, T.W., & Hs, B.G. (2008). Single dose intravenous thioacetamide administration as a model of acute liver damage in rats. *International Journal of Experimental Pathology*, 89, 223–231.
- [24] Abdel-Salam, O.M.E., Youness, E.R., Sleem, A.A., & Morsy, F.A. (2022). Citric acid administration protects against insulin-induced hypoglycemic brain and liver injury. *WSEAS TRANSACTIONS on BIOLOGY and BIOMEDICINE*, 19, 31-40.

- [25] Abdel-Salam, O.M., Youness, E.R., Mohammed, N.A., Morsy, S.M., Omara, E.A., & Sleem, A.A. (2014a). Citric acid effects on brain and liver oxidative stress in lipopolysaccharide-treated mice. *Journal of Medicinal Food*, 17(5), 588–98.
- [26] Abdel-Salam, O.M., Youness, E.R., Mohammed, N.A., Yassen, N.N., Khadrawy, Y.A., El-Toukhy, S.E., et al. (2016). Novel neuroprotective and hepatoprotective effects of citric acid in acute malathion intoxication. *Asian Pacific Journal of Tropical Medicine*, 9(12), 1181–94.
- [27] Abdel-Salam, O.M.E., Morsy, S.M.Y., Youness, E.R., Yassen, N.N., Shaffie, N., & Sleem, A.A. (2020a). Citric acid protects dopaminergic cells against rotenone-induced neurodegeneration. *Reactive Oxygen Species* 9(27), 118–135.
- [28] Abdel-Salam, O.M.E., Sleem, A.A., Morsy, F.A. (2020b). Citric acid protects against toluene-induced brain neurodegeneration and liver damage in rats. *Journal of Basic Pharmacology and Toxicology*, 4(2), 38-48.
- [29] La Du, B.N. (1992). Human Serum Paraoxonase: Arylesterase. Pergamon Press, New York, NY, USA.
- [30] Watson, A.D., Berliner, J.A., Hama, S.Y., La Du, B.N., Faull, K.F., Fogelman, A.M., et al. (1995). Protective effect of high density lipoprotein associated paraoxonase: inhibition of the biological activity of minimally oxidized low density lipoprotein. *Journal of Clinical Investigation*, 96(6), 2882–91.
- [31] Ferre, N., Camps, J., Prats, E., Vilella, E., Paul, A., Figuera, L., & Joven, J. (2002). Serum paraoxonase activity: a new additional test for the improved evaluation of chronic liver damage. *Clinical Chemistry*, 48, 261–268.
- [32] Baskol, M., Baskol, G., Deniz, K., Ozbakir, O., & Yucesoy, M. (2005). A new marker for lipid peroxidation: serum paraoxonase activity in non-alcoholic steatohepatitis. *Turkish Journal of Gastroenterology*, 16(3), 119–123.
- [33] Abdel-Salam, O.M.E., El-Shamarka, M.E-S., Hassan, N.S., & Abouelfadl, D.M. (2021). Effect of piracetam on brain oxidative stress and tissue damage following toluene exposure in rats. *International Journal of Halal Research*, 3(1), 8-23.
- [34] Camps, J., Marsillach, J., & Joven, J. (2009). Measurement of serum paraoxonase-1 activity in the evaluation of liver function. *World Journal of Gastroenterology*, 15(16), 1929–33.
- [35] Furlong, C.E., Marsillach, J., Jarvik, G.P., & Costa, L.G. (2016). Paraoxonases-1, -2 and -3: what are their functions? *Chemico-Biological Interactions*, 259(Pt B), 51–62.
- [36] Abdel-Salam, O.M.E., El-Shamarka, M.E-S., Shaffie, N., & Gaafar, A.E-D.M. (2014b). Study of the effect of *Cannabis sativa* on liver and brain damage caused by thioacetamide. *Comparative Clinical Pathology*, 23 (3), 495-507.
- [37] de Carvalho, M.A., Popov, S.S., Safonova, O.A., Makeeva, A.V., Matasova, L.V., Pashkov, A.N., & Popova, T.N. (2010). The effects of some substances-protectors on free-radical homeostasis in diseases associated with oxidative stress. In “Handbook of Free Radicals Formation, Types and Effects”. (Kozyrev D, & Slutsky V, eds.), Nova Science Publishers, pp. 291-303.
- [38] Kristinova, V., Aaneby, J., Mozuraityte, R., Storrø, I., & Rustad, T. (2014). The effect of dietary antioxidants on iron-mediated lipid peroxidation in marine emulsions studied by measurement of dissolved oxygen consumption. *European Journal of Lipid Science and Technology*, 116, 857–871.
- [39] Tungsanga, K., Sriboonlue, P., Futrakul, P., Yachantha, C., & Tosukhowong, P. (2005). Renal tubular cell damage and oxidative stress in renal stone patients and the effect of potassium citrate treatment. *Urological Research* 33, 65-69.
- [40] Moncada, S., & Bolanos, J.P. (2006). Nitric oxide, cell bioenergetics and neurodegeneration. *Journal of Neurochemistry*, 97(6), 1676–89.
- [41] Forstermann, U., & Sessa, W.C. (2012). Nitric oxide synthases: regulation and function. *European Heart Journal*, 33(7), 829–37, 37a–37d.
- [42] Gritters, M., Grooteman, M.P., Schoorl, M., Schoorl, M., Bartels, P.C., Scheffer, P.G., et al. (2006). Citrate anticoagulation abolishes degranulation of polymorphonuclear cells and platelets and reduces oxidative stress during haemodialysis. *Nephrology Dialysis Transplantation*, 21(1), 153-159.

-
- [43] Ying, W., Chen, Y., Alano, C.C., & Swanson, R.A. (2002). Tricarboxylic acid cycle substrates prevent PARP-mediated death of neurons and astrocytes. *Journal of Cerebral Blood Flow & Metabolism*, 22(7), 774–779.
- [44] Izumi, Y., & Zorumski, C.F. (2010). Neuroprotective effects of pyruvate following NMDA-mediated excitotoxic insults in hippocampal slices. *Neuroscience Letters*, 478(3), 131–135.
- [45] Puntel, R.L., Nogueira, C.W., & Rocha, J.B.T. (2005). Krebs cycle intermediates modulate thiobarbituric acid reactive species (TBARS) production in rat brain in vitro. *Neurochemical Research*, 30(2), 225-235.
- [46] Haces, M.L., Hernandez-Fonseca, K., Medina-Campos, O.N., Montiel, T., Pedraza-Chaverri, J., & Massieu, L. (2008). Antioxidant capacity contributes to protection of ketone bodies against oxidative damage induced during hypoglycemic conditions. *Experimental Neurology*, 211(1), 85–96.